



Contents lists available at ScienceDirect

European Journal of Obstetrics & Gynecology and Reproductive Biology

journal homepage: www.elsevier.com/locate/ejogrb

Outcome of perineoplasty and de-adhesion in patients with vulvar Lichen sclerosus and sexual disorders

Fabienne Lauber^a, Inês Vaz^b, Jörg Krebs^c, Andreas R. Günthert^{b,*}^a Department of Obstetrics and Gynecology, Cantonal Hospital of Lucerne, Lucerne, Switzerland^b gyn-zentrum ag, Lucerne, Switzerland^c Clinical Trial Unit, Swiss Paraplegic Centre, Nottwil, Switzerland

ARTICLE INFO

Article history:

Received 31 August 2020

Received in revised form 16 December 2020

Accepted 18 December 2020

Available online xxx

Keywords:

Vulvar Lichen sclerosus

Perineoplasty

De-Adhesion

Dyspareunia

Sexual activity

Fissura granulatum

ABSTRACT

Objective: Vulvar Lichen sclerosus (LS) is a chronic inflammatory disease in which architectural changes and symptoms like itching, soreness, pain and dyspareunia can affect quality of life and sexual activity. Perineoplasty has been shown to be effective as a supportive surgical treatment in women with refractory dyspareunia in addition to the standard topical immunosuppressive treatment. The aim of this study was to evaluate retrospectively general complaints, patient satisfaction concerning sexual activity, reduction of dyspareunia/apareunia, orgasm ability and recurrence of LS after perineoplasty.

Study design: This study is a retrospective monocentric observational study, in which patients with vulvar LS who had undergone perineoplasty were invited to fill out a standardized questionnaire during the follow-up time. The main outcome measure is the overall patient satisfaction after surgical therapy of vulvar LS.

Results: Forty-one of the 70 invited patients with a median age at surgery of 58 years (18–74 years) and a median 60 years (19–76 years) at the last follow-up were evaluated. The median follow-up time was 2.3 years (1–5 years). There was a significant ($p < 0.001$) reduction in general complaints after surgery. Twenty-two patients were very satisfied, 15 were satisfied and 3 were not satisfied with the outcome of the surgery. Only 2 patients would not recommend the surgery. Although, there was a significant ($p = 0.02$) reduction in dyspareunia after surgery, 10 patients still felt pain during sexual intercourse.

Conclusion: This is one of the largest studies reporting on long-term results of perineoplasty. It showed that perineoplasty is a safe surgical treatment option with a high satisfaction rate in patients with dyspareunia due to LS and a desire to regain sexual activity.

Perineoplasty can improve sexual activity and achieve overall satisfaction in selected patients even though the recurrence rate of LS in sexually active patients remains high.

© 2020 Published by Elsevier B.V.

Introduction

Vulvar Lichen sclerosus (LS) is a chronic inflammatory disease, allegedly affecting elderly women in the anogenital area. However, there is evidence that LS has its onset already in younger women or even in children. The high rate of familial LS suggests a genetic contribution possibly linked to recurrent germ-line variants in four genes [1–5]. Vulvar LS can cause scarring of genitalia including agglutination of the labia minora, phimosis of the clitoris and narrowing of the introitus [3,6–11]. Quality of life and sexual activity deteriorate, if these architectural changes become

permanent [3,5,8,10]. Early changes and symptoms associated with LS, such as itch, soreness, pain and dyspareunia or lower urinary tract symptoms (LUTS) are not specific, which leads to a delayed diagnosis in a number of patients [3,5,10,12]. However, some women present with advanced LS without ever showing symptoms [3,6,10]. The challenge for physicians is to recognize alterations of the vulva, particularly if patients present with recurrent unspecific symptoms and a suspected infection. Unfortunately, histologic examination of a biopsy is often not characteristic and can cause additional pain, scarring and psychological distress [1,3,7,11,13–15]. The etiology of the disease is still not fully understood, but the immunomodulatory pathogenesis is the most common hypothesis.

The currently established treatment strategy is local immune suppression by very potent topical corticoid ointments or calcineurin inhibitors. The optimal maintenance treatment, however and

* Corresponding author at: gyn-zentrum ag, Haldenstrasse 11, 6006 Lucerne, Switzerland.

E-mail address: andreas.guenther@gyn-zentrum.ch (A.R. Günthert).

recommendations regarding the extent of monitoring remain unclear [3,6,8–10]. Surgical treatment should be reserved for symptomatic patients in order to restore the architectural changes caused by scarring and agglutination, such as recurrent tearing during intercourse (vulvar granuloma fissuratum), stenosis and phimosis with decreased clitoral sensation. Perineoplasty (modified Fenton's procedure), during which the posterior fourchette is excised and replaced by a tension-free vaginal advancement flap, was shown to be a safe procedure in these patients, with a low complication and a high satisfaction rate [16–20]. Other surgical treatments are the lysis of the labial fusion, dehooding of the clitoral glans in case of phimosis (de-adhesion) and anterior vestibuloplasty with vaginal epithelium grafts [18–20]. Perineoplasty provides good functional results, enabling patients to resume or regain painless vaginal intercourse with a high satisfaction rate. However, there is a lack of knowledge regarding the long-term results of these procedures, and the cohorts in these studies were usually small.

Aim

The aim of this study was to retrospectively evaluate patient satisfaction after perineoplasty and de-adhesion in patients with adequately treated vulvar LS, focusing on improvement in sexual activity, reduction of dyspareunia/apareunia and restoration of the ability to experience orgasm. Secondly, the recurrence of LS was investigated.

Material and methods

Participants and procedure

This study is a retrospective monocentric observational study with data collection from the internal database of the tertiary referral vulvar outpatient clinic at the Department of Obstetrics and Gynecology of the Cantonal Hospital of Lucerne, Switzerland. The data of women who underwent a standardized vulvar surgery due to clinically or histologically confirmed LS and dyspareunia/apareunia between June 2013 and June 2018 were collected.

Perineoplasty was performed according to a modified Fenton's procedure [16–18], with defined surgical steps and suture materials. Peri- and postoperative treatment followed a strict protocol; daily topical treatment with clobetasolpropionate or mometasone ointment) and instruction for postoperative use of vaginal dilators). Patients were pretreated with daily corticoid ointment for at least two weeks, and postoperative treatment was continued for another four weeks. Thereafter, patients were encouraged to maintain a therapy with two applications of corticoid ointment per week. Patients were also encouraged and instructed to use vaginal dilators (Vagiwell®) starting four weeks after the surgery. Surgical treatment was only performed by two of us (I.V., A.G.). In some cases, additional surgery, such as de-adhesion for clitoris exposure or of labial synechia, was performed. In all patients, excised specimens were analyzed histologically. Patients were all instructed to apply hygienic measures and local disinfection, and the surgical wounds were inspected at least weekly until healing was complete. Patients were then instructed regarding pelvic floor training and vaginal dilatation.

Inclusion criteria were histologically or clinically (Lichen score ≥ 4) [2] verified vulvar LS, perineoplasty, minimum age 18 years, dyspareunia/apareunia due to scarring of the posterior fourchette and signed written consent. Exclusion criteria were deviations in the perineoplasty technique, follow-up shorter than 12 months and inadequate German language skills.

Pretreatment symptoms such as dyspareunia, apareunia, burning and itching were recorded in our database following a standard in-house protocol. For the long-term follow-up, all

participants were invited by letter to fill-out a standardized questionnaire. Phone calls were made, if necessary, to increase the recall rate. The questionnaire contained the following items:

- general complaints such as burning or itching before surgery, 3 months after surgery and now (scale 1–10, 0= no complaints, 10= extreme complaints)
- dyspareunia/apareunia after the surgery (yes/ no)
- ability to experience orgasm after the surgery (yes/ no)
- recurrence of LS (yes/ no)
- overall satisfaction with the surgery (very satisfied/ satisfied/ not satisfied)
- recommendation of the treatment (yes/ no)

The severity of the general complaints was the primary outcome. The secondary outcomes were sexual activity, dyspareunia/apareunia, ability to experience orgasm, recurrence of the introitus stenosis and overall satisfaction with the surgery.

Calculation

The collected data were summarized calculating the median and the quartiles. The changes in the severity of the general complaints over time (before surgery, 3-months after surgery and last follow-up) were investigated using the Brunner model [21] for the non-parametric (rank-based) analysis of variance of longitudinal data. Post-hoc testing was performed with the Wilcoxon signed-ranks. The Chi-square or Fisher's exact test were used to investigate differences in the observed frequencies.

The statistical analyses were performed using the SPSS software (Version 25, IBM, Somers, NY, USA) or the R software environment (Version 3.4.0, Copyright 2017, The R Foundation for Statistical Computing). A p-value of ≤ 0.05 was considered significant.

The Ethics Committee of Northwestern and Central Switzerland approved the study (Nr. 2018–00124).

Results

Patient's characteristics

Seventy patients, who were eligible for the study, were identified in our database and invited to participate in the study. A total of 41 patients (57.7 %) returned the questionnaire for analysis. Thus, the available data of these 41 patients were evaluated. All patients had undergone perineoplasty. In 18 patients, additional clitoral phimosis was treated by de-adhesion. All patients complied with the pre- and post-surgery treatment. One patient refused the corticoid maintenance therapy. Vaginal dilators were used by 27 patients (65.9 %). The median age of patients at the time of surgery was 58 years (range 18–74 years), the median age at time of evaluation was 60 years (19–76 years). At the time of the evaluation (09/2018), 31 (75.6 %) patients were over and 10 (24.4 %) under 50 years old. The median follow-up time was 2.3 years (range 1–5 years).

Excised tissue of all 70 patients was analyzed. No precancerous lesion was found in any sample. We recorded only 1 (1.4 %) minor wound break down due to infection, which did not require re-surgery.

Primary outcome: severity of general complaints

The complaints and their frequency preoperatively are summarized in Table 1. There was a significant ($p < 0.001$) reduction in general complaints over time. There was a significant ($p < 0.001$) decrease in the severity of general complaints (severity scale from 1 to 10) from a median 8.0 before surgery to a median 4.0 3 months

Table 1

Pre-operative complaints and their frequency in absolute number of patients and percentage to total number of patients including in the study.

Measurement	Number of patients
itching	33 (80.5 %)
burning sensation	31 (75.6 %)
genital pain	23 (56.1 %)
genital fissures	34 (82.9 %)
dyspareunia	35 (85.4 %)
pain after sexual intercourse	28 (68.3 %)
apareunia	26 (63.4 %)
no orgasm	6 (14.6 %)
urination problems	16 (39.0 %)
urinary tract infections	9 (22.0 %)
defecation problems	8 (19.5 %)

after surgery. Furthermore, the severity score decreased

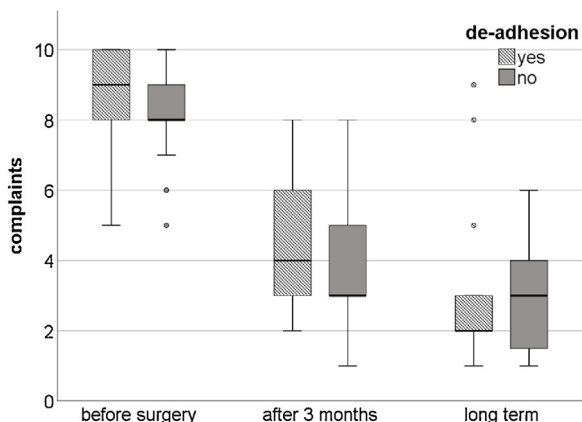


Fig. 1. Boxplots which show the severity of the general complaints before, 3 months after and at the last follow-up (at least 12 months) after vulvar surgery for the 41 evaluated patients and additional de-adhesion in 18 patients. General complaints contain: itching, burning, pain in the genital region, cracks in the genital region, dyspareunia, pain after sexual intercourse, apareunia, no orgasm possible, problems urinating, urinary tract infections, problems with bowel movement. Boxplots show the median, interquartile range and minimum/maximum.

Table 2

Summary of the secondary outcomes.

Measurement		Number of patients	p-value
Sexually active postoperatively (> 2 x/ month)	yes	26 (63.4 %)	na
	no	13 (31.7 %)	
	no information	2 (4.9 %)	
Pain during intercourse postoperatively?	yes	10 (24.4 %)	na
	no	17 (41.5 %)	
	no information	14 (34.1 %)	
Dyspareunia	preop	35 of 41 (85.4 %)	<0.001
	postop	10 of 27 (37.0 %)	
Improvement in sexual life?	yes	28 (68.3 %)	na
	no	10 (24.4 %)	
	no information	3 (7.3 %)	
Improvement in sexual life?	sexually active	23 of 25 (92 %)	<0.001
	not sexually active	3 of 11 (27.3 %)	
	very satisfied	22 (53.7 %)	
Satisfaction rate	satisfied	15 (36.6 %)	na
	not satisfied	3 (7.3 %)	
	no information	1 (2.4 %)	
	with de-adhesion	16 of 18 (88.9 %)	
Very satisfied, satisfied	without de-adhesion	21 of 23 (91.3 %)	0.9
	yes	33 (80.5 %)	
Ability to orgasm postoperatively?	no	5 (12.2 %)	na
	no information	3 (7.3 %)	
	yes	39 (95.1 %)	
Recommendation of surgery?	no	1 (2.4 %)	na
	no information	1 (2.4 %)	
	yes	39 (95.1 %)	

significantly ($p = 0.007$) from 3 months after surgery to a median 2.0 at the last follow-up (at least 12 months after surgery) (Fig. 1).

Secondary outcomes: sexual activity, dyspareunia/apareunia, ability to experience orgasm, recurrence of the introitus stenosis and overall satisfaction after surgical treatment

Overall, patients recorded a significant reduction of dyspareunia after surgery ($p = 0.02$). Twenty-eight patients (68.3 %) reported a better sexual life after surgery, 10 patients (24.4 %) recorded no improvement and 3 (7.3 %) gave no information. Patients who were sexually active after surgery reported significantly ($p = 0.001$) more often to have a better sexual life compared to those who were not sexually active. There was no significant ($p = 0.5$) difference in the number of sexually active patients between those who used a vaginal dilator and those who did not. Data concerning the secondary outcomes are presented in Table 2.

Before surgery, information regarding the ability to experience orgasm was only available for 6 patients. Three of these 6 patients were again able to experience an orgasm after surgery and 3 had no sexual activity after surgery. There was no significant ($p = 0.4$) difference in the number of very satisfied and satisfied patients between those having the ability to experience orgasm and those who do not.

No patient required surgery during the follow-up. However, 2 of the 18 patients who underwent de-adhesion reported recurrent prepuce agglutination. Twenty-three patients (56.1 %, including the patient who refused maintenance therapy) required intensified topical treatment during the follow-up period due to LS activity.

Out of the 41 patients who returned the questionnaire, 22 (53.7 %) were very satisfied with the result, 15 (36.6 %) were satisfied and 3 (7.3 %) were not satisfied. Thirty-nine patients (95.1 %) would recommend the surgery, 1 (2.4 %) would not recommend it, and 1 (2.4 %) did not give any information (Table 2).

Discussion

To our knowledge, this is one of the largest studies reporting long-term results of perineoplasty and de-adhesion in patients

with vulvar Lichen sclerosus and sexual disorders. Previous and this study showed that perineoplasty and de-adhesion can improve sexual satisfaction in these patients [16–20,22]. In earlier studies, the success rate regarding reduction of dyspareunia was very high, which was probably due to using other outcome parameters and performing surgery only in highly selected patients [16,18]. However, more recent studies reported that surgery improved the sexual life in the majority of patients, but most patients were still experiencing pain during intercourse [19,22–24]. These findings correlate with our study, in which one third of the patients was not sexually active after surgery. Perineoplasty additional to conservative management seems to be superior in the treatment of scarring and recurrent fissures in the posterior fourchette in comparison to conservative management alone [25]. In accordance with previous studies, we have observed a high number of patients with recurrent LS activity (56.1 %), which may have been triggered by sexual activity [8,24]. Rangatchew et al. described an increase in dyspareunia/apareunia after surgery in sexually active women as a result of LS relapse [24]. This is in contrast to our study, in which we did not find a correlation. Brauer et al. investigated the motives of women with LS undergoing surgery, and interestingly, the main motives were the desire to be a “normal” woman, the desire to sexually satisfy the male partner, and the desire to regain the experience of intimacy and sexual enjoyment [26]. In our study the overall satisfaction had improved after surgery, although more than 30 % of the patients did not have sexual intercourse after surgery, based on different reasons. Fear, psychological distress or habituated omission of sexual activity were the most common reasons for not having sexual intercourse patients reported and not persistent complaints due to LS. More than 90 % of our patients would recommend the procedure, even though so many were not sexually active after surgery. Just being able to have intercourse and having a normal vulva results in overall satisfaction. This is in accordance with the findings of Hodges et al., that women with vulvar LS have a significantly decreased Female Genital Self-Image Scale (FGSIS), which correlates with sexual function [27]. Several other factors affect women’s sexual life in addition to LS, such as conditioned vulvodynia, pelvic floor and vagina spasms, LUTS and psychological aspects. Some of our patients also report sensory symptoms, which might not only be due to agglutinations, but driven by the damage of small nerve fibers during the course of the disease [28]. Perioperative measures to limit/stop LS activity, detailed treatment instructions, surveillance to avoid complications after surgery, preoperative sexual and psychologic counselling in addition to the couple-based sexual history are essential for a good surgical outcome and were taken seriously in the care of our patients. Prior to surgery, the motives for undergoing vulvar surgery and the expectations regarding the surgical outcome need to be clarified and discussed in order to achieve treatment satisfaction [23,26,27]. In our study, therefore, a preoperative consultation took place before the procedure.

A limitation of our study is, that not all patients have participated. It can or must be assumed that these patients who did not participate were rather dissatisfied with the perineoplasty. This falsifies our study results into a more positive direction than it may actually be.

In case the perineoplasty procedure is not successful or as a potential surgical alternative, there are novel approaches for the surgical treatment of vulvar LS. Frapell et al. described a double opposing Z-plasty with VY advancement of the perineum (Plymouth procedure) and reported good outcomes, in particular in patients with persisting complaints after the modified Fenton’s procedure [29]. Fat grafting and adipose-derived stem cells or platelet-rich plasma treatments are currently introduced and have

the potential to be supportive procedures in refractory cases [30,31]. Finally, non-ablative laser techniques are currently being investigated in clinical trials with encouraging results [32,33].

Conclusion

In selected patients with a desire for improved sexual activity, vulvar surgery is a very good option to regain overall satisfaction in patients with LS. Following a standardized treatment protocol is essential to prevent complications and to fulfill preoperatively defined expectations. The recurrence rate of LS activity in sexually active women is high, and thus, these patients require long-term monitoring and interdisciplinary support.

Declaration of Competing Interest

The authors declare that they have no known competing financial interests or personal relationships that could have appeared to influence the work reported in this paper.

Acknowledgements

All authors have no conflict of interest.

We would like to thank Michelle Larson for proofreading the manuscript.

References

- [1] Günthert AR, Faber M, Knappe G, Hellriegel S, Emons G. Early onset vulvar Lichen Sclerosus in premenopausal women and oral contraceptives. *Eur J Obstet Gynecol Reprod Biol* 2008;137:56–60, doi:<http://dx.doi.org/10.1016/j.ejogrb.2007.10.005>.
- [2] Sherman V, McPherson T, Baldo M, Salim A, Gao XH, Wojnarowska F. The high rate of familial lichen sclerosus suggests a genetic contribution: an observational cohort study. *J Eur Acad Dermatol Venereol* 2010;24:1031–4, doi:<http://dx.doi.org/10.1111/j.1468-3083.2010.03572.x>.
- [3] Kirtschig G, Cooper S, Aberer W, et al. Evidence-based (S3) Guideline on (anogenital) Lichen sclerosus. *J Eur Acad Dermatol Venereol* 2017;31:e81–3, doi:<http://dx.doi.org/10.1111/jdv.13740>.
- [4] Haefner HK, Welch KC, Rolston AM, et al. Genomic profiling of vulvar lichen sclerosus patients shows possible pathogenetic disease mechanisms. *J Low Genit Tract Dis* 2019;23:214–9, doi:<http://dx.doi.org/10.1097/LGT.0000000000000482>.
- [5] Morrel B, van Eersel R, Burger CW, et al. The long-term clinical consequences of juvenile vulvar lichen sclerosus: a systematic review. *J Am Acad Dermatol* 2020;82:469–77, doi:<http://dx.doi.org/10.1016/j.jaad.2019.08.030>.
- [6] Smith YR, Haefner HK. Vulvar lichen sclerosus: pathophysiology and treatment. *Am J Clin Dermatol* 2004;5:105–25, doi:<http://dx.doi.org/10.2165/00128071-200405020-00005>.
- [7] Günthert AR, Ducloux K, Jahns BG, et al. Clinical scoring system for vulvar lichen sclerosus. *J Sex Med* 2012;9:2342–50, doi:<http://dx.doi.org/10.1111/j.1743-6109.2012.02814.x>.
- [8] Lee A, Bradford J, Fischer G. Long-term management of adult vulvar lichen sclerosus: a prospective cohort study of 507 women. *JAMA Dermatol* 2015;151:1061–7, doi:<http://dx.doi.org/10.1001/jamadermatol.2015.0643>.
- [9] Lee A, Fischer G. Diagnosis and treatment of vulvar lichen sclerosus: an update for dermatologists. *Am J Clin Dermatol* 2018;19:695–706, doi:<http://dx.doi.org/10.1007/s40257-018-0364-7>.
- [10] Lewis FM, Tatnall FM, Velangi SS, et al. British Association of Dermatologists guidelines for the management of lichen sclerosus, 2018. *Br J Dermatol* 2018;178:839–53, doi:<http://dx.doi.org/10.1111/bjd.16241>.
- [11] Sheinis M, Selk A. Development of the adult vulvar lichen sclerosus severity Scale-A delphi consensus exercise for item generation. *J Low Genit Tract Dis* 2018;22:66–73, doi:<http://dx.doi.org/10.1097/LGT.0000000000000361>.
- [12] Christmann-Schmid C, Hediger M, Gröger S, Krebs J, Günthert AR. In cooperation with the Verein Lichen sclerosus. Vulvar lichen sclerosus in women is associated with lower urinary tract symptoms. *Int Urogynecol J* 2018;29:217–21, doi:<http://dx.doi.org/10.1007/s00192-017-3358-8>.
- [13] Regauer S, Liegl B, Reich O. Early vulvar lichen sclerosus: a histopathological challenge. *Histopathology* 2005;47:340–7, doi:<http://dx.doi.org/10.1111/j.1365-2559.2005.02209.x>.
- [14] Kreklau A, Vaz I, Oehme F, et al. Measurements of a ‘normal vulva’ in women aged 15–84: a cross-sectional prospective single-centre study. *BJOG* 2018;125:1656–61, doi:<http://dx.doi.org/10.1111/1471-0528.15387>.
- [15] McCarthy S, MacEoin N, O’Driscoll M, O’Connor R, CCBB Heffron, Murphy M. Should We Always Biopsy in Clinically Evident Lichen Sclerosus? *J Low Genit Tract Dis* 2019;23:182–3, doi:<http://dx.doi.org/10.1097/LGT.0000000000000457>.

- [16] Rouzier R, Haddad B, Deyrolle C, Pelisse M, Moyal-Barracco M, Paniel BJ. Perineoplasty for the treatment of introital stenosis related to vulvar lichen sclerosis. *Am J Obstet Gynecol* 2002;186:49–52, doi:<http://dx.doi.org/10.1067/mob.2002.119186>.
- [17] Goldstein A. Perineoplasty and vaginal advancement flap for vulvar granuloma fissuratum. *J Sex Med* 2011;8:2984–7, doi:<http://dx.doi.org/10.1111/j.1743-6109.2011.02528.x>.
- [18] Gurumurthy M, Morah N, Gioffre G, Cruickshank ME. The surgical management of complications of vulval lichen sclerosis. *Eur J Obstet Gynecol Reprod Biol* 2012;162:79–82, doi:<http://dx.doi.org/10.1016/j.ejogrb.2012.01.016>.
- [19] Flynn AN, King M, Rieff M, Krapf J, Goldstein AT. Patient satisfaction of surgical treatment of clitoral phimosis and labial adhesions caused by lichen sclerosis. *Sex Med* 2015;13(3):251–5, doi:<http://dx.doi.org/10.1002/sm2.90>.
- [20] Burger MP, Obedeijn MC. Complications after surgery for the relief of dyspareunia in women with lichen sclerosis. *Acta Obstet Gynecol Scand* 2016;95:467–72, doi:<http://dx.doi.org/10.1111/aogs.12852>.
- [21] Brunner E, Domhof S, Langer F. Nonparametric analysis of longitudinal data in factorial experiments. New York: Wiley; 2002.
- [22] Bradford J, Fischer G. Surgical division of labial adhesions in vulvar lichen sclerosis and lichen planus. *J Low Genit Tract Dis* 2013;17:48–50, doi:<http://dx.doi.org/10.1097/LGT.0b013e31824f1427>.
- [23] Brauer M, van Lunsen RH, Laan ET, Burger MP. A Qualitative Study on Experiences After Vulvar Surgery in Women with Lichen Sclerosis and Sexual Pain. *J Sex Med* 2016;13:1080–90, doi:<http://dx.doi.org/10.1016/j.jsxm.2016.04.072>.
- [24] Rangatchew F, Knudsen J, Thomsen MV, Drzewiecki KT. Surgical treatment of disabling conditions caused by anogenital lichen sclerosis in women: an account of surgical procedures and results, including patient satisfaction, benefits, and improvements in health-related quality of life. *J Plast Reconstr Aesthet Surg* 2017;70:501–8, doi:<http://dx.doi.org/10.1016/j.bjps.2016.12.008>.
- [25] Kennedy CM, Dewdney S, Galask RP. Vulvar granuloma fissuratum: a description of fissuring of the posterior fourchette and the repair. *Obstet Gynecol* 2005;105:1018–23, doi:<http://dx.doi.org/10.1097/01.AOG.0000158863.70819.53>.
- [26] Brauer M, van Lunsen R, Burger M, Laan E. Motives for vulvar surgery of women with lichen sclerosis. *J Sex Med* 2015;12:2462–73, doi:<http://dx.doi.org/10.1111/jsm.13052>.
- [27] Hodges KR, Wiener CE, Vyas AS, Turrentine MA. The female genital self-image scale in adult women with vulvar lichen sclerosis. *J Low Genit Tract Dis* 2019;23:210–3, doi:<http://dx.doi.org/10.1097/LGT.0000000000000481>.
- [28] Milian-Ciesielska K, Chmura L, Dyduch G, Jagers C, Radwanska E, Adamek D. Intraepidermal nerve fiber density in vulvar lichen sclerosis and normal vulvar tissues. *J Physiol Pharmacol* 2017;68:453–8.
- [29] Frappell J, Rider L, Riadin L, Ebeid E, Asmussen T, Morris R. Double Opposing Zplasty with VY Advancement of the perineum: long-term results of a new technique as an alternative to Fenton's operation for narrowing and splitting of the skin at the posterior vaginal fourchette. *Eur J Obstet Gynecol Reprod Biol* 2018;223:46–9, doi:<http://dx.doi.org/10.1016/j.ejogrb.2018.02.003>.
- [30] Boero V, Brambilla M, Sipio E, et al. Vulvar lichen sclerosis: a new regenerative approach through fat grafting. *Gynecol Oncol* 2015;139:471–5, doi:<http://dx.doi.org/10.1016/j.ygyno.2015.10.014>.
- [31] Eshtiagh P, Sadownik LA. Fact or fiction? Adipose-derived stem cells and platelet-rich plasma for the treatment of vulvar lichen sclerosis. *J Low Genit Tract Dis* 2019;23:65–70, doi:<http://dx.doi.org/10.1097/LGT.0000000000000440>.
- [32] Bizjak Ogrinc U, Senčar S, Luzar B, Lukanović A. Efficacy of non-ablative laser therapy for lichen sclerosis: a randomized controlled trial. *J Obstet Gynaecol Can* 2019;41:1717–25, doi:<http://dx.doi.org/10.1016/j.jogc.2019.01.023>.
- [33] Preti M, Vieira-Baptista P, Digesu GA, et al. The clinical role of LASER for vulvar and vaginal treatments in gynecology and female urology: an ICS/ISSVD best practice consensus document. *J Low Genit Tract Dis* 2019;23:151–60, doi:<http://dx.doi.org/10.1097/LGT.0000000000000462>.



Inês Vaz is a Consultant doctor at the gyn-zentrum ag in Lucerne, Switzerland since June 2018. After graduating from the Medical Faculty (2004) of the University of Porto, Portugal she worked as a resident doctor in the department of obstetrics and gynecology at the Center Hospital of Porto, Portugal as well as the Cantonal Hospital in Lucerne, Switzerland. She holds the subspecialty of gynecologic surgery (2016) and a doctorate of medicine (2018) from the Medical Faculty of the University of Bern, Switzerland.



Jörg Krebs has been a Senior Research Fellow at the Clinical Trial Unit of the Swiss Paraplegic Centre in Nottwil, Switzerland for the past decade. He holds a Doctorate of Veterinary Medicine (2002) from the Faculty of Veterinary Medicine and a PhD in Biomedical Engineering (2007, summa cum laude) from the Medical Faculty of the University of Bern, Switzerland. He has authored or co-authored more than 70 peer-reviewed publications and is currently appointed to the Editorial Boards of Spinal Cord (Nature) and Spinal Cord Series and Cases.



Andreas Günthert holds a MD Thesis (1999) from the Medical Faculty of the University of Heidelberg, Germany as well as a *venia legendi* (2006) from the Medical Faculty of the University of Göttingen, Germany. In 2013 he was appointed as associated professor of the medical faculty of the University of Berne, Switzerland. After being the Head of the Department of Obstetrics and Gynecology (2013–2018) at the Cantonal Hospital of Lucerne, Switzerland he has founded the gyn-zentrum ag in Lucerne, Switzerland in June 2018.



Fabienne Lauber is a resident doctor in the department of gynecology and obstetrics at the Cantonal Hospital of Lucerne, Switzerland. After graduating from the Medical Faculty of the University of Zurich, Switzerland (2017) she worked in the department of gynecology and obstetrics at the Cantonal Hospital of Zug, Switzerland for 1.5 years. With this research study she aims to receive the doctorate of medicine.